



# Zirconia Implants and All-Ceramic Restorations for the Esthetic Replacement of the Maxillary Central Incisors

**Josep Oliva, MSc**

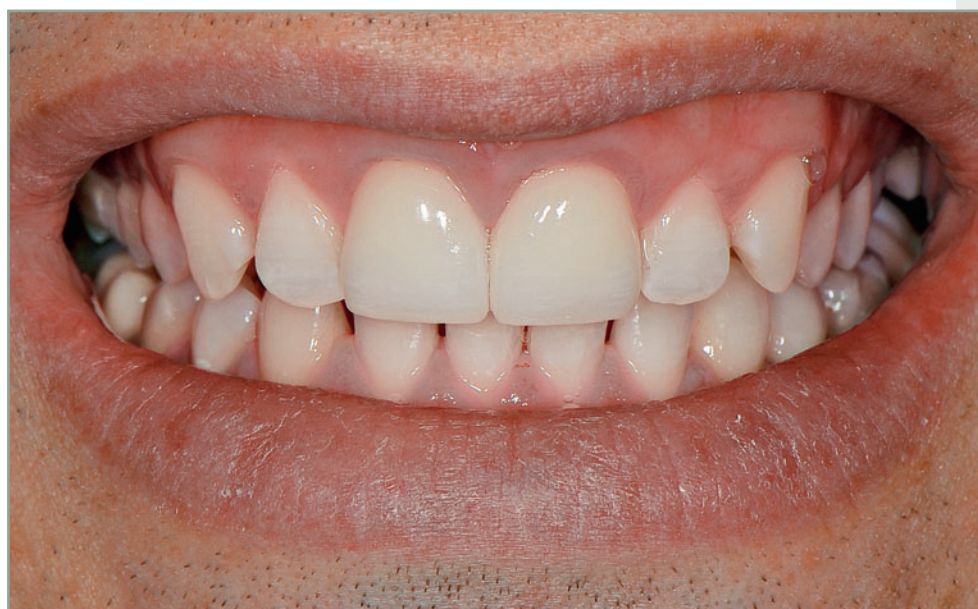Private Practice  
Granollers, Barcelona, Spain

**Xavi Oliva, MSc**

Private Practice  
Granollers, Barcelona, Spain

**Josep D. Oliva, DMD**

Private Practice  
Granollers, Barcelona, Spain



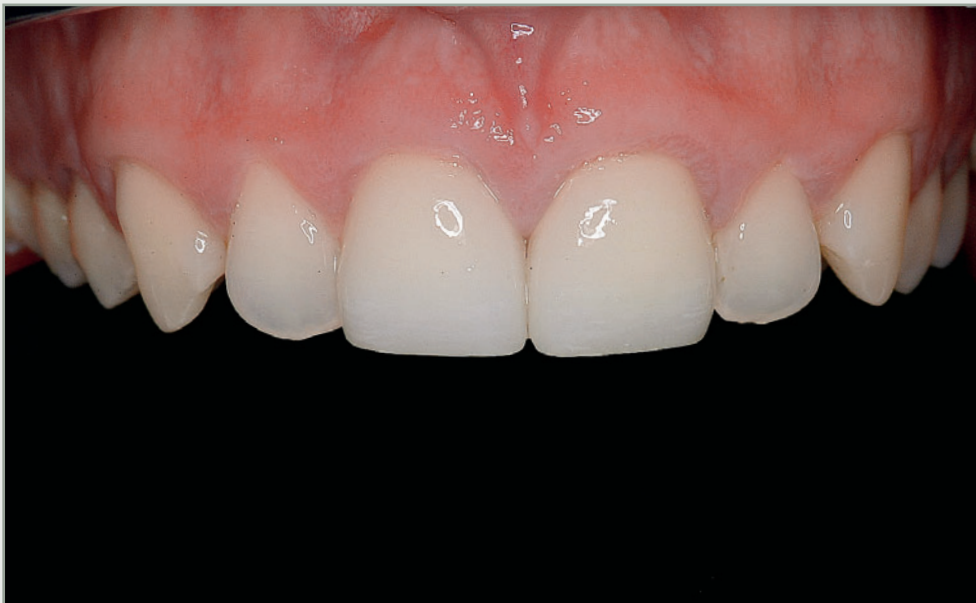Correspondence to: Dr Josep Oliva  
126 Josep Umbert, 08400 Granollers, Barcelona, Spain;  
fax: +34 938792373; e-mail: laclinica@clinicaoliva.com.

## Abstract

Ceramics have been used in dentistry and medicine for many years. Today, one of the most popular ceramics is zirconia because of its outstanding mechanical properties, which make it suitable for many indications formerly reserved for metals. Zirconia-based ceramics have been used for many years as the core for single crowns and long-span fixed prostheses. Zirconia-based ceramics have also been used as implants for hip replacements and finger, toe, and wrist joints. Recently, some articles in the dental literature suggest the possible use of zirconia implants for tooth replacement. The present case report illustrates the results that can be achieved using rough-surface

zirconia implants in an esthetically demanding case. The 28-year-old male patient required replacement of the maxillary central incisors. Two rough-surface zirconia implants (CeraRoot) were used to immediately replace the extracted teeth. Immediate provisional restorations were placed for a period of 3 months until the final all-ceramic restorations were cemented. Zirconia implants may be a good alternative for tooth replacement, especially in esthetically demanding cases. More studies are needed to evaluate the long-term results of zirconia dental implants with different surfaces.

*(Eur J Esthet Dent 2008;3:174–185.)*





The material of choice for dental implants is commercially pure titanium due to its well-documented biocompatibility<sup>1</sup> and suitability for tooling. This material has been used for about 30 years as implant substrate with good success rates.<sup>2</sup> One possible alternative to titanium is tooth-colored materials such as ceramics.<sup>3,4</sup> Ceramic materials are highly biocompatible and can be used as dental devices.<sup>5</sup> One ceramic material that was used in the past for dental implants was aluminum oxide.<sup>6-8</sup> This material showed good osseointegration, but did not have sufficient mechanical properties for long-term loading and was withdrawn from the market.

Recently, another ceramic material with potential as a dental implant material was introduced. Zirconia possesses good physical properties, such as flexural strength (900 to 1,200 MPa), hardness (1,200 Vickers), and Weibull modulus (10 to 12).<sup>9-11</sup> Marx et al<sup>12</sup> stressed the importance of the threshold stress intensity factor of zirconia ( $K_{10} = 3.1 \pm 0.2 \text{ MPa}\sqrt{\text{m}}$ ) for determining long-term stability. Furthermore, its biocompatibility has been demonstrated in several animal investigations.<sup>13-20</sup> In vitro experiments showed that the material is capable of withstanding simulated long-term load; however, the mechanical properties of zirconia seem to be influenced by the mechanical preparation of the material.<sup>17,21</sup> Moreover, the exposure of zirconia implants to the artificial mouth has no statistically significant influence on the mean fracture strength values of the implants.<sup>21</sup> Kohal et al<sup>22</sup> published a case report of a machined zirconia implant and zirconia crown in one patient, achieving an excellent esthetic result. Modern implant research shows that a rough surface topography is desirable to enhance the bone

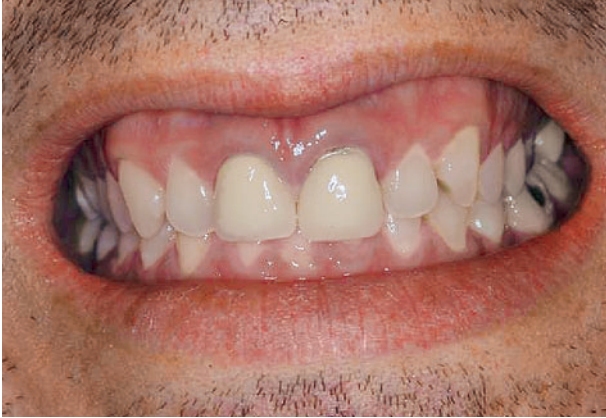integration process,<sup>23</sup> but the turning of zirconia rods results in a relatively smooth surface. Sennerby et al<sup>20</sup> demonstrated better implant retrieval torque resistance of porous zirconia surfaces in rabbits. In a recent publication, Oliva et al<sup>24</sup> studied the 1-year survival rate of 100 rough-surface zirconia implants in humans, and reported a success rate comparable to titanium implants. The one-piece zirconia implants used in this study (CeraRoot) had a rough surface, and no mechanical preparation of the abutment was needed for the final restoration.

## Case presentation

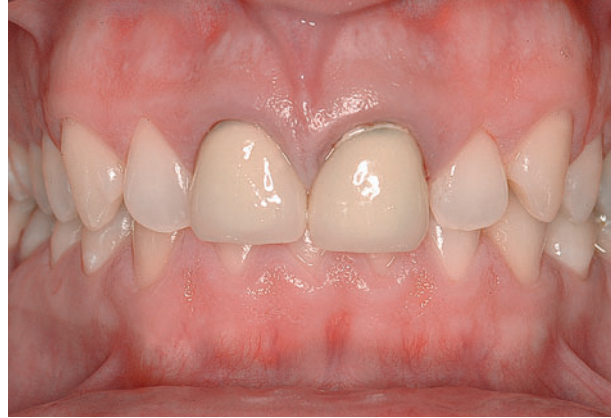The patient was a 28-year-old man who was a nonsmoker in good general health. The patient presented for an initial examination with pain at the maxillary left central incisor, and loosening of the crowns on both maxillary central incisors (Figs 1 to 4). He was also concerned about the esthetics of his smile. The dental history revealed that he had broken the central incisors while playing basketball at age 18. Root canal treatment had been performed and two metal-ceramic crowns were placed. The patient reported that the crowns were very loose and that he had been back to his dentist many times for recementation. The patient was concerned about metal materials and requested a metal-free tooth replacement and metal-free restoration.

### Initial examination

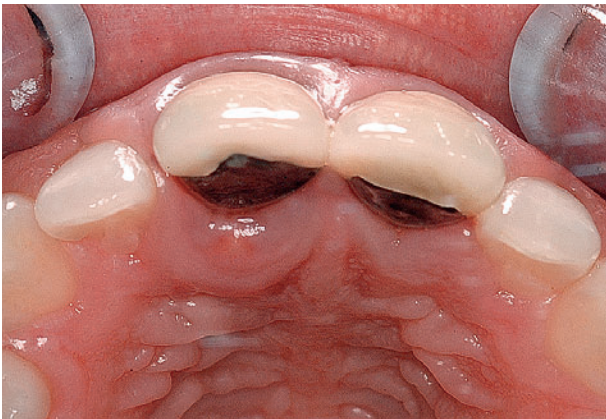After an initial examination and periapical radiographs, the authors confirmed a root fracture on the left central incisor. There was also high mobility with palatal inflammation and periapical chronic lesions (Figs



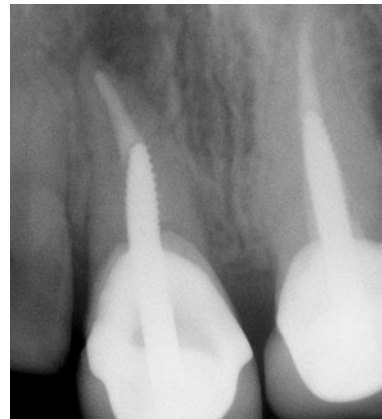**Fig 1** The patient had a high smile line, with dark coloration visible through the gums.



**Fig 2** Intraoral view of the preoperative situation.



**Fig 3** Occlusal view showing palatal inflammation.



**Fig 4** Radiograph showing the periapical lesion at the left central incisor.

3 and 4). The papilla between the central incisors was inflamed (Figs 1 and 2). Esthetically, the metal from the restoration was visible in the margin of the restoration and the dark color of the root was visible through the gingiva, even though the patient showed a thick soft tissue biotype. The smile line was very high, with more than 5 mm of gums visible above the central incisors. A deep bite was present due to the

extrusion of the mandibular incisors and maxillary central incisors. The occlusion was Class I on the right side and Class II on the left side. There were interproximal open embrasures in the mandibular anterior region. The mandibular right first molar had been endodontically treated and showed a chronic periapical lesion, which the patient decided to have treated at a later time.




## Treatment plan

Systemic antibiotics were administered for 4 days before surgery and 7 days after surgery. The maxillary central incisors were considered hopeless teeth and planned for extraction. The patient asked for a metal-free restoration. The patient was informed about the possibility of zirconia implants and all-ceramic restorations, and he requested this treatment. One-piece root form zirconia implants were selected (CeraRoot). As seen in Fig 5, the implant has a transgingival part with a scalloped design to support the interproximal tissues. Additionally, the design of the abutment is such that there is no need to prepare it for the provisional or final restoration.

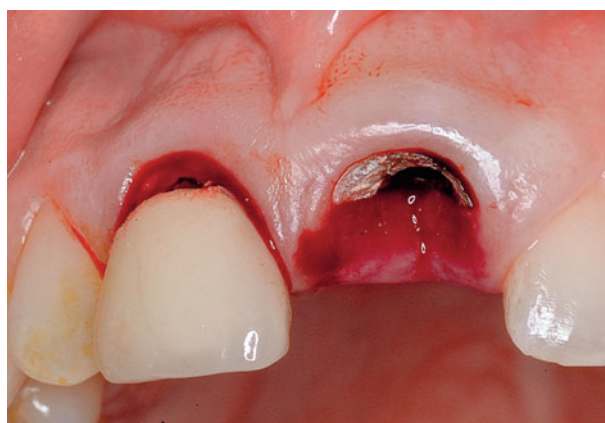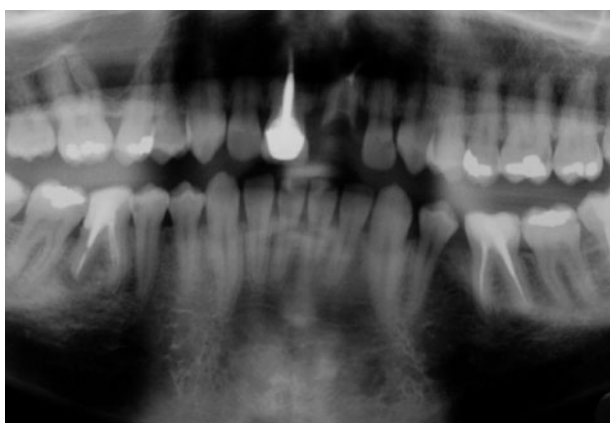
## Surgical treatment

The surgical treatment started with atraumatic teeth and root extractions using scalpels and forceps (Figs 6 to 9). The extraction sockets were debrided and the chronic periapical cyst was extracted followed by irrigation with saline solution. The drilling sequence used two pilot drills followed by twist drills. Special care was taken

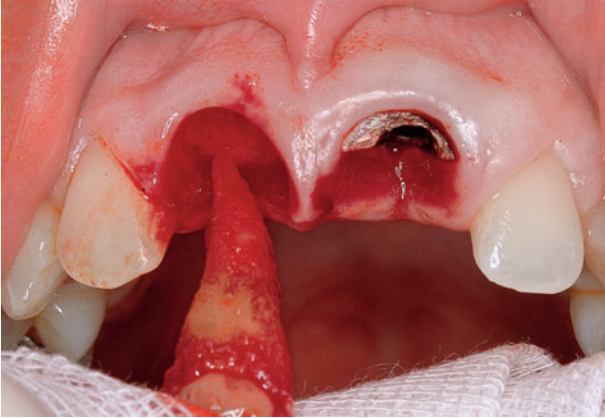


**Fig 5** Frontal (left) and interproximal (right) views of the CeraRoot zirconia implant.

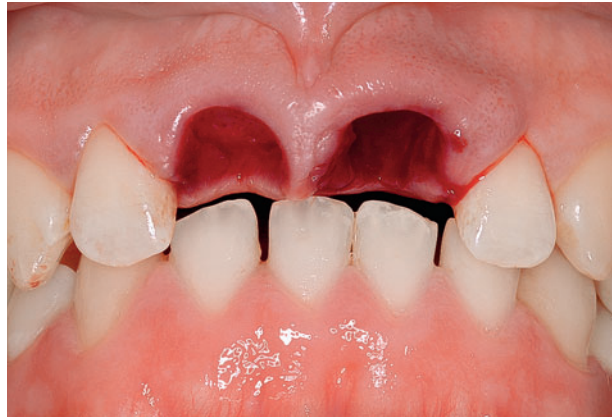to give the drills the appropriate inclination to follow the incisal edge of the two missing teeth (Figs 10 and 11). A profile drill was used to finalize the shape of the implant site. The implants were inserted at the contra-angle using a special key. The implant buccal shoulder was left 1.5 mm apically to the lateral incisors to compensate for the extrusion of the old central incisors (Figs 12 and 13). An optimal primer stability ( $> 35$  N) of both implants was achieved at surgery.



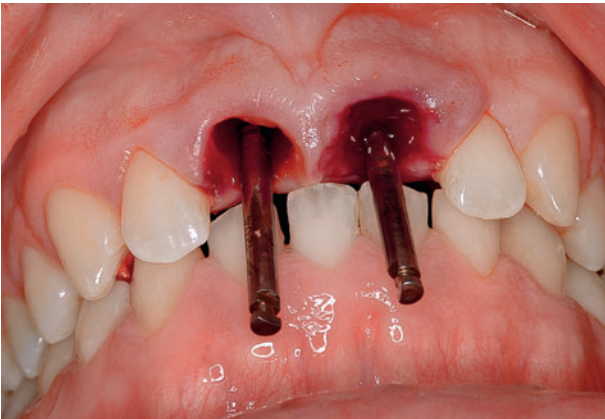**Figs 6 and 7** Radiograph and intraoral view following extraction of the left central incisor.



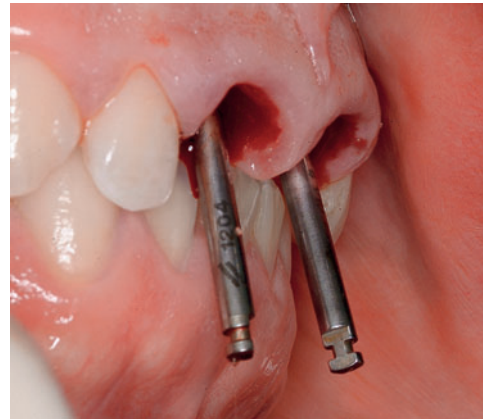**Fig 8** Extraction of the right central incisor.



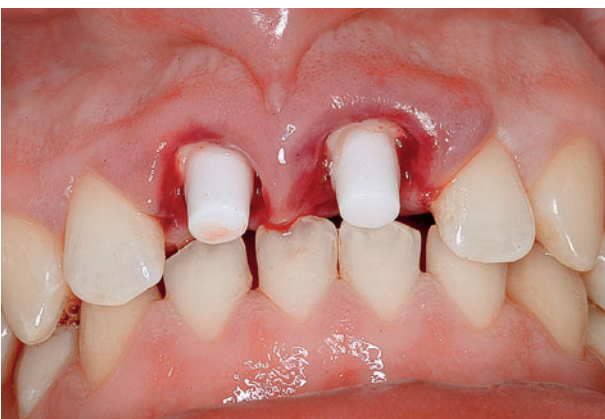**Fig 9** Frontal view following extraction of the central incisors.



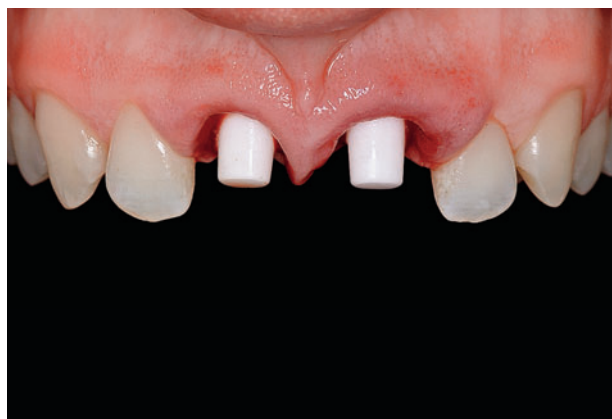**Fig 10** Implant site preparation with optimal inclination.



**Fig 11** Drilling must be performed in the direction of the final crown.



**Fig 12** Placement of zirconia implants in the optimal occlusal direction.



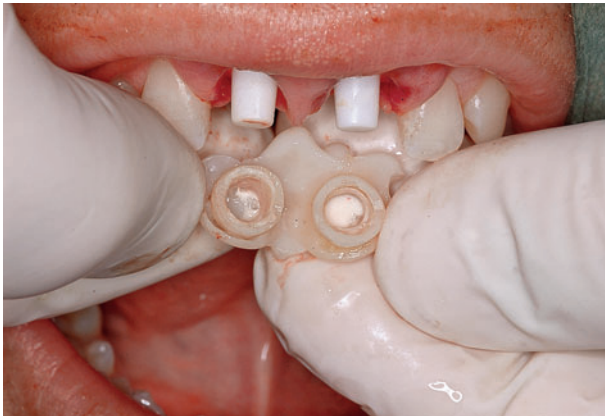
**Fig 13** Zirconia implants in place. Note the integrity of the papilla due to the atraumatic surgery.



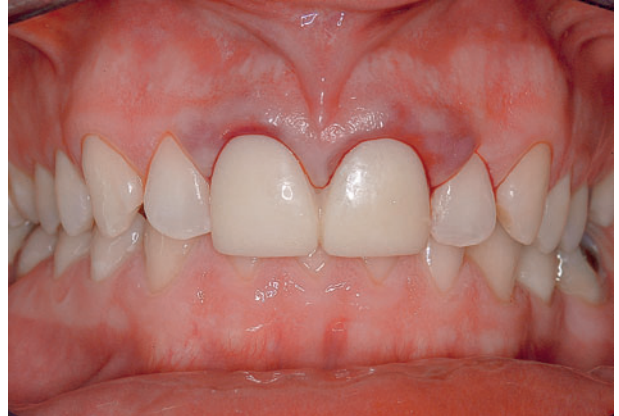### Immediate provisional restoration

The provisionals were fabricated before surgery with standard resin. To adjust the provisionals to the implants, prefabricated resin caps with the implant shoulder were used (Fig 14). Photopolymerizing composite (Protemp, 3M ESPE) was used to assemble the prefabricated provisional restorations and resin caps. The excess composite was then removed and the provisionals were polished. Special care was

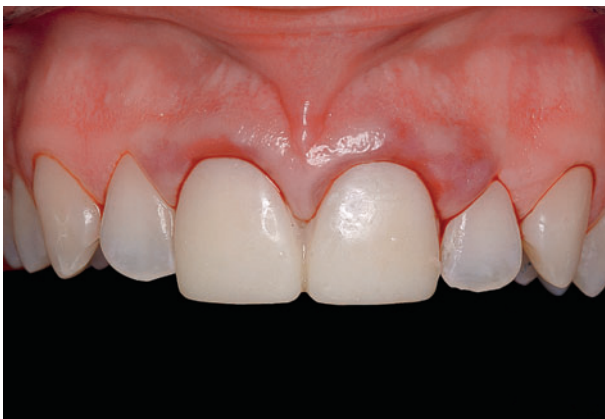taken to leave the provisionals out of occlusion, and the patient was informed that he should not use this provisional restoration for at least 1 month. For temporary cementation, light-curing cement was used (Provilink TM, Ivoclar-Vivadent) (Figs 15 and 16). Immediately following cementation, panoramic radiographs were taken to confirm the adequate fit of the provisional restoration and the correct position of the zirconia implants (Fig 17).



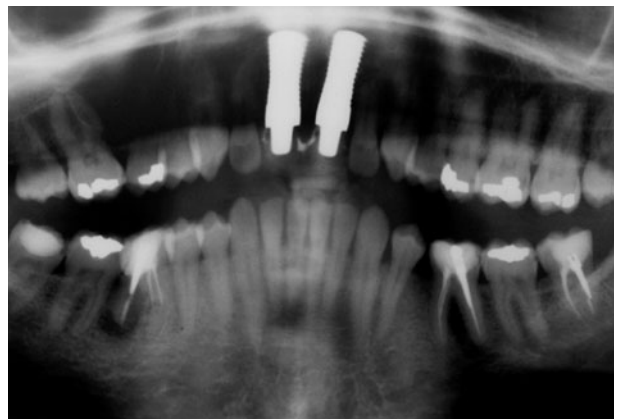**Fig 14** Prefabricated provisional restoration is adapted to the zirconia implants using prefabricated resin caps and composite.



**Fig 15** Immediate provisional in place. Cementation is carried out with temporary cement.



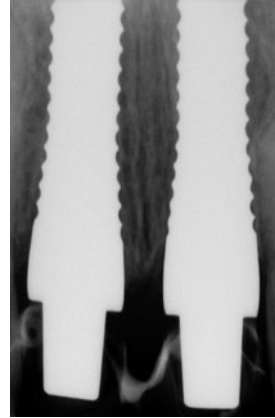
**Fig 16** The esthetic appearance is acceptable immediately after surgery.



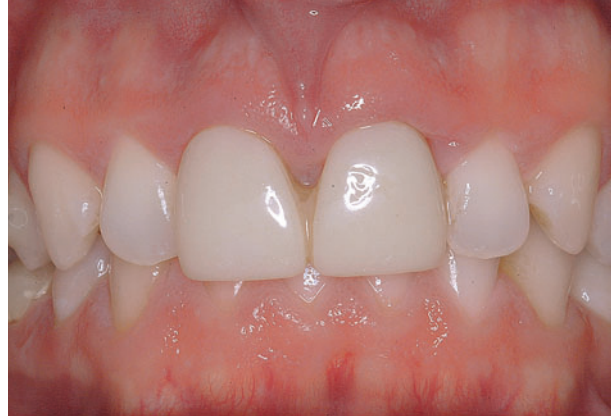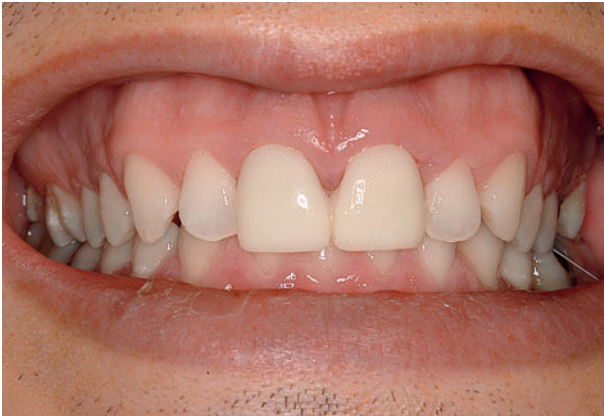**Fig 17** Panoramic radiograph following cementation of the provisional restoration.

### Healing period

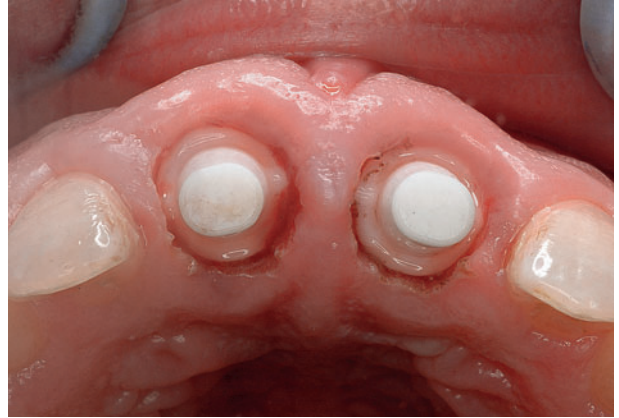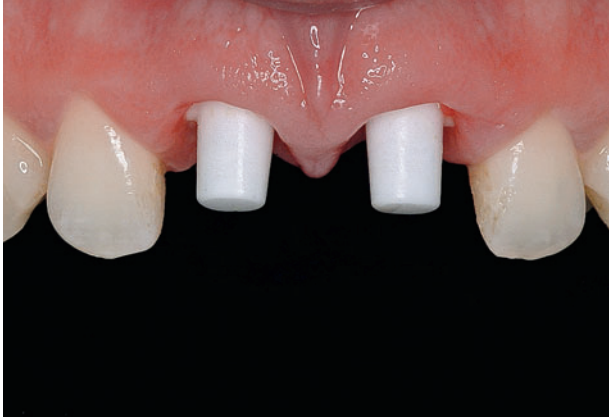Fifteen days postsurgery, the appearance of the soft tissues was very good and little inflammation was visible (Figs 18 to 20). The patient reported high satisfaction at this point because he did not feel much pain and had no bleeding. The patient was seen every 2 weeks for clinical, photographic, and radiographic assessment. No problems were reported during the 3-month healing period.



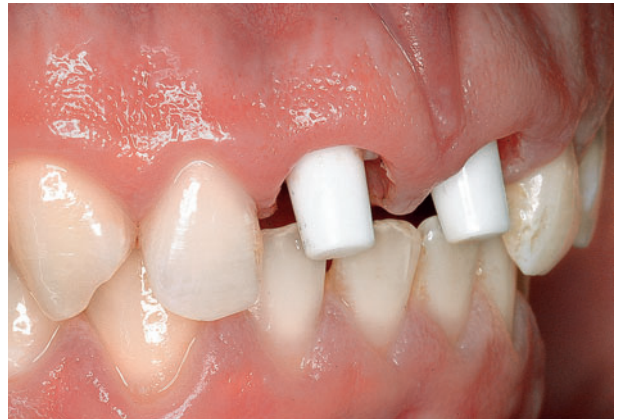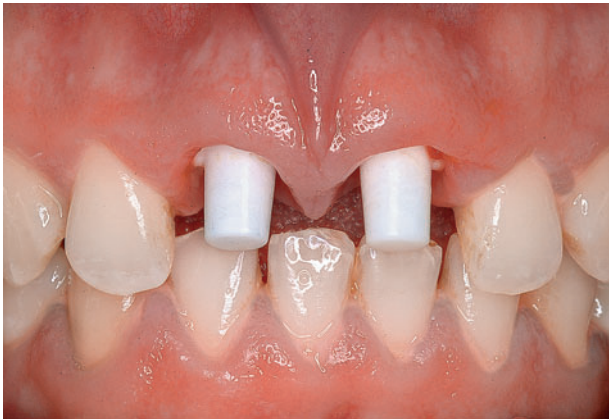**Fig 18** Periapical radiograph 15 days postsurgery.



**Figs 19 and 20** Optimal soft tissue adaptation was evident 15 days postsurgery.



**Figs 21 and 22** The provisionals were removed 3 months postsurgery for final impression taking. Note that the soft tissue volume is greatly preserved.

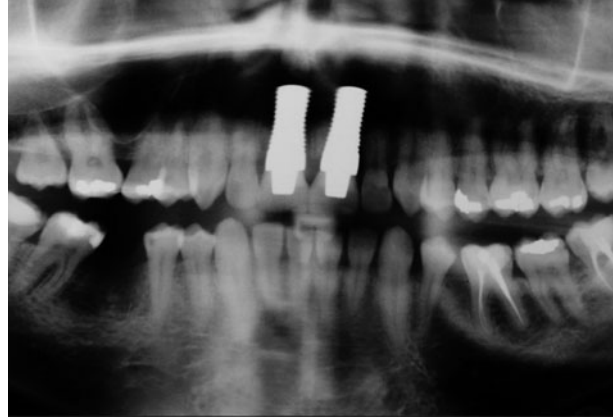
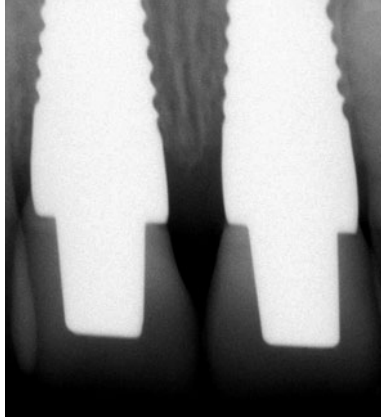


**Figs 23 and 24** Frontal and lateral views in occlusion. Note the adequate positioning of the implants for the final restoration.

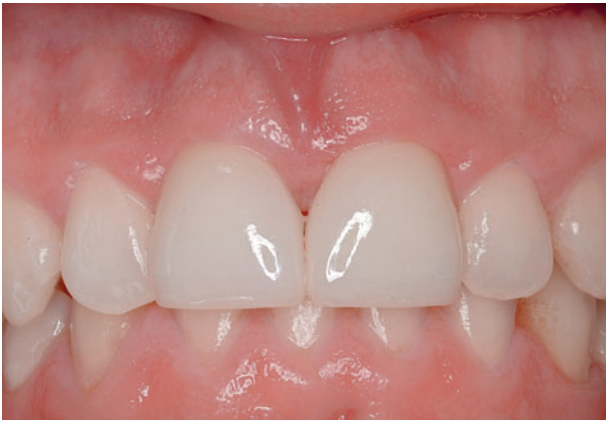### Final restoration

Three months after surgery, the soft tissues had healed perfectly around the zirconia implants and provisional restoration (Figs 21 to 24). No inflammation or bleeding was present around the implants. The papilla between the implants was intact, and the color of the gums was identical to those around the neighboring teeth, giving the impression of a natural look. At this time, an

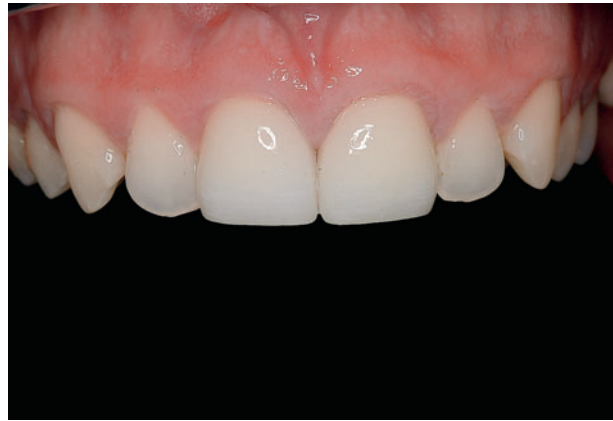electrosurgery unit (Martin) was used to remove any excess soft tissue around the implant shoulder. Impressions for the final restorations were taken with polyether (Impregum, 3M ESPE) without using retraction cords. The final restoration was fabricated with an all-ceramic system (Empress II, Ivoclar-Vivadent), and the final cementation (Figs 25 to 27) was carried out 4 months after surgery with resin modified glass-



**Figs 25 and 26** Periapical and panoramic radiographs to confirm the fit of the final all-ceramic restoration and optimum position of the zirconia implants.



**Fig 27** Cementation of the final restorations. The gums still need to adapt to the new restoration.

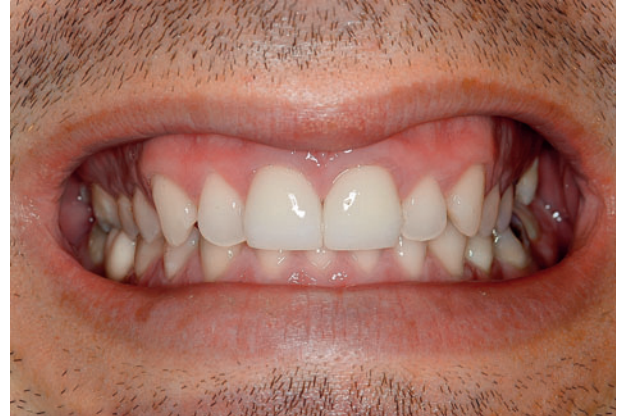
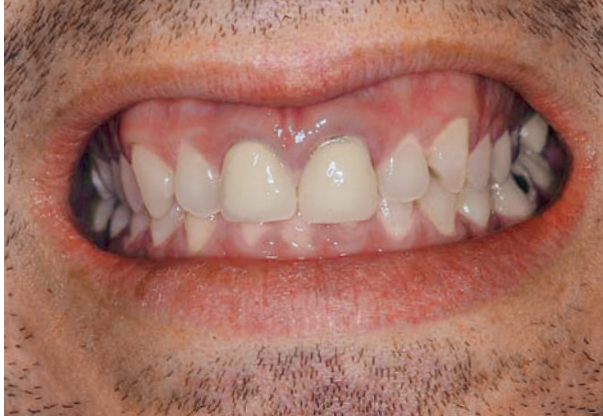
**Fig 28** One-year follow-up. Note the perfect integration of soft tissues with the all-ceramic restoration.

ionomer cement (GC FujiCEM, GC America). Special attention was given to the occlusion to avoid excess contact in centric and protrusive displacements. A slight infraocclusion was left to compensate for the periodontal ligament of the neighboring teeth. Periapical and panoramic radiographs were taken to confirm the adequate fit of the restoration (Figs 25 and 26).

### Follow-up

The 1-year follow-up showed high stability of the implants and gums (Fig 28), and the patient reported no adverse symptoms or complaints. The esthetic appearance was greatly improved and the patient was very satisfied with the final result (Figs 29 and 30).



**Figs 29 and 30** Before and after photographs. After treatment there is no difference in the soft tissue color around natural teeth and zirconia implants. The all-ceramic restoration has a natural look.

## Discussion

When using zirconia implants to restore teeth, the latest implant research should be taken into consideration. The biocompatibility of zirconia has been demonstrated in several animal investigations.<sup>13-20</sup> Also, in vitro experiments showed that the material is capable of withstanding simulated long-term load; however, the mechanical properties of zirconia seem to be influenced by the mechanical preparation of the material.<sup>17,21</sup> The same authors reported that the exposure of zirconia implants to the artificial mouth has no statistically significant influence on the mean fracture strength values of the implants. Moreover, modern implant research shows that a rough surface topography is desirable to enhance the bone integration process,<sup>23</sup> but the turning of zirconia rods results in a relatively smooth surface. Sennerby et al<sup>20</sup> demonstrated better implant retrieval torque resistance of porous zirconia surfaces in rabbits. In a recent publication, Oliva et al<sup>24</sup> studied the 1-year survival rate of 100 rough-surface zirconia implants in hu-

mans and reported a success rate comparable to titanium implants. The one-piece zirconia implants used in this study had a rough surface, and no mechanical preparation of the abutment was needed for the final restoration.

It is important to exercise careful case selection when using zirconia implants. Since only cemented restorations can be used, the implant must be placed in the perfect position and inclination. A surgical guide is useful in this regard. It is also important to have good and stable occlusion to avoid placing too much stress on the implants.

## Conclusions

Zirconia implants may be a good alternative for tooth replacement, especially in esthetically demanding cases. More studies are needed to evaluate the long-term results of zirconia implants with different surfaces.



## References

- Kasemo B, Lausmaa J. Biomaterial and implant surfaces: A surface science approach. *Int J Oral Maxillofac Implants* 1988;3:247–259.
- Kasemo B, Lausmaa J. Biomaterials and interfaces. In: Naert I, van Steenberghe D, Worthington P (eds). *Osseointegration in Oral Rehabilitation*. London: Quintessence, 1993: 63–75.
- Heydecke G, Kohal R, Glaser R. Optimal esthetics in single-tooth replacement with the Re-Implant system: A case report. *Int J Prosthodont* 1999;12: 184–189.
- Wohlwend A, Studer S, Schärer P. The zirconium oxide abutment—A new all-ceramic concept for esthetically improving suprastructures in implantology [in German]. *Quintessenz Zahntech* 1996;22:364–381.
- Silva VV, Lameiras FS, Lobato ZI. Biological reactivity of zirconia-hydroxyapatite composites. *J Biomed Mater Res* 2002;63: 583–590.
- Schulte W. The intra-osseous Al<sub>2</sub>O<sub>3</sub> (Frialit) Tuebingen Implant. Developmental status after eight years (I–III). *Quintessence Int* 1984;15:1–39.
- Schulte W, d'Hoedt B. Thirteen years of the Tuebingen implant system made by Frialit—additional results [in German]. *Z Zahnärztl Implantol* 1988;3: 167–172.
- De Wijs FLJA, Van Dongen RC, De Lange GL. Front tooth replacement with Tuebingen (Frialit) implants. *J Oral Rehabil* 1994;21:11–26.
- Marx R. Modern ceramic materials for esthetic restorations—Strengthening and fracture toughness [in German]. *Dtsch Zahnärztl Z* 1993;48: 229–236.
- Piconi C, Burger W, Richter HG, et al. Y-TZP ceramics for artificial joint replacements. *Biomaterials* 1998;19: 1489–1494.
- Stevens R. Zirconia and Zirconia Ceramics. An Introduction to Zirconia, ed 2. Twickenham, UK: Litho, 2000:1–51.
- Marx R, Jungwirth F, Walter P. Threshold intensity factors as lower boundaries for crack propagation in ceramics. *BioMedical Engineering Online* 2004;3:41.
- Albrektsson T, Hansson HA, Ivarsson B. Interface analysis of titanium and zirconium bone implants. *Biomaterials* 1985;6:97–101.
- Akagawa Y, Ichikawa Y, Nikai H, Tsuru H. Interface histology of unloaded and early loaded partially stabilized zirconia endosseous implant in initial bone healing. *J Prosthet Dent* 1993;69:599–604.
- Akagawa Y, Hosokawa R, Sato Y, Kamayama K. Comparison between freestanding and tooth-connected partially stabilized zirconia implants after two years' function in monkeys: A clinical and histological study. *J Prosthet Dent* 1998;80:551–558.
- Ichikawa Y, Akagawa Y, Nikai H, et al. Tissue compatibility and stability of a new zirconia ceramic in vivo. *J Prosthet Dent* 1992;68:322–326.
- Kohal R J, Papavasiliou G, Kamposiora P, Tripodakis A, Strub J. Three-dimensional computerized stress analysis of commercially pure titanium and yttrium-partially stabilized zirconia implants. *Int J Prosthodont* 2002;15:189–194.
- Kohal R J, Weng D, Bächle M, Strub J. Loaded custom-made zirconia and titanium implants show similar osseointegration. *J Periodontol* 2004;75: 1262–1268.
- Kohal RJ, Hürzeler MB, Mota LF, et al. Custom-made root analogue titanium implants placed into extraction sockets. An experimental study in monkeys. *Clin Oral Implants Res* 1997;8:386–392.
- Sennerby L, Dasmah A, Larsson B, Iverhed M. Bone tissue responses to surface-modified zirconia implants: A histomorphometric and removal torque study in the rabbit. *Clin Implant Dent Relat Res* 2005;7 Suppl 1:s13–s20.
- Andreiotelli M. Survival Rate And Fracture Resistance of Zirconium Dioxide Implants After Exposure to the Artificial Mouth: An In-Vitro Study [thesis]. Freiburg, Germany: University of Freiburg, 2006.
- Kohal R J, Klaus G. A zirconia implant/zirconia crown system. A case report. *Int J Periodontics Restorative Dent* 2004;24: 147–153.
- Wennerberg A. On surface roughness and implant incorporation [thesis]. Göteborg: University of Göteborg, 1996.
- Oliva J, Oliva X, Oliva DJ. One-year follow-up of first consecutive 100 zirconia dental implants in humans. A comparison of two different rough surfaces. *Int J Oral Maxillofac Implants* 2007;22:430–435.