

Biomechanical and Clinical Attributes of Zirconia Dental Implants — Two Case Reports

Dan Hagi DDS, FAGD, FICOI, (A)FAAID

INTRODUCTION

The last three decades have seen an increase in the use of dental implants to replace missing teeth. The use of Titanium root form implants in the rehabilitation of the partially or completely edentulous patient has been rooted in the work of Dr. Branemark in the late 1970s and is based on the fact that titanium implants “osseointegrate” with native bone and the material has the physical properties needed for oral function. It is widely accepted that the clinical outcome of titanium implants in terms of rigid fixation and long term functional success is good, however, negative aesthetic late complications and soft tissue recession are widespread especially in the esthetic zone.³ These late complications have led to many implant collar design changes and to the advent of white zirconia transgingival abutments in an attempt to minimize soft tissue recession and hide the metallic color and grey hue of the gingiva and in an effort to reduce aesthetic failures.¹⁰ A possible alternative to the use of titanium is the use of ceramic as the material for the dental implants. One such material is Zirconia (Y-TZP),

possessing the capacity to osseointegrate^{1,2,11-13} and very favourable physical properties, such as flexural strength (900-1200MPa), hardness (1200 Vickers) as well as a favorable threshold stress intensity factor (10-12) all needed for long term stability and success.^{7,9} Moreover, the one piece design and white colour simplify esthetic rehabilitation of the partially edentulous. The following two case presentations will show how the acid-etched CeraRoot zirconia Implant (Oral Iceberg, Granoller, Barcelona) can be used to functionally and aesthetically replace both anterior and posterior teeth and achieve optimal soft tissues and health.

CASE 1 PRESENTATION

Diagnosis

The patient, a 44-year-old female, non-smoker in good general health, presented with a missing tooth #22. History revealed that the tooth was extracted due to failed endodontic treatment and was currently replaced with a removable partial denture. Radiographic and clinical exam revealed that bone volume was adequate in all dimensions and soft tissue was thick and

keratinized, with a small buccal deficiency (Figs. 1-3). Occlusion was stable and even though tooth #32 was in buccal version, enough restorative space was available. Some recession was noted on her upper canines with otherwise healthy periodontal tissues. The smile line was high and a highly aesthetic outcome was desired.

Treatment Plan

As the patient wanted a fixed restoration options were discussed including an option of a conventional fixed bridge, bonded Maryland type-bridge or a implant retained crown. An implant was the preferred treatment option. The possibility of the use of a zirconia one-piece dental implant (CeraRoot, Oral Iceberg) was discussed and the alternative titanium option was also discussed. Due to the high smile line and high esthetic expectation we decided to utilize a CeraRoot zirconia dental implant and an all-ceramic E.max (Ivoclar-Vivadent, Liechtenstein) crown.

Surgical Treatment

The patient was pre-medicated with an antibiotic (Amoxicillin 500mg), which was to be contin-

CASE 1

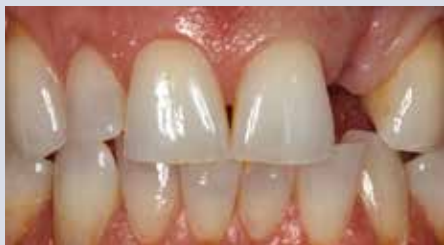

FIGURE 1—Pre-operative condition.

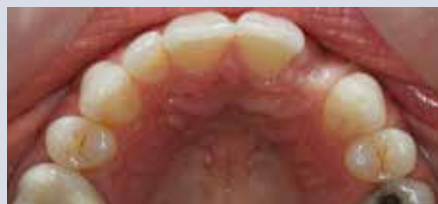

FIGURE 2—Pre-operative occlusal view.

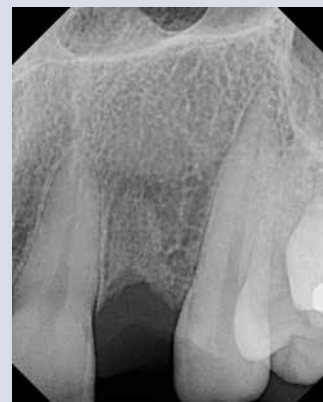

FIGURE 3—Pre-operative radiograph.

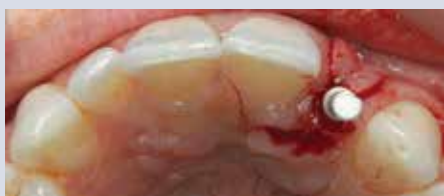

FIGURE 4—Site preparation and drill angulation.

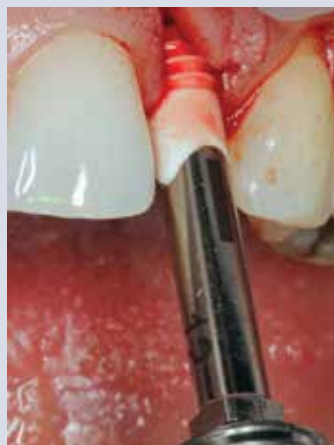

FIGURE 5—Implant being inserted with stainless steel driver.

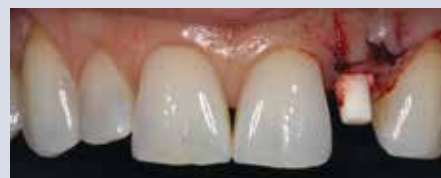

FIGURE 6—Immediately post surgery showing implant position.

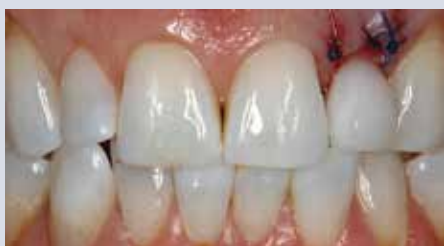

FIGURE 7—Provisional crown cemented immediately after surgery.

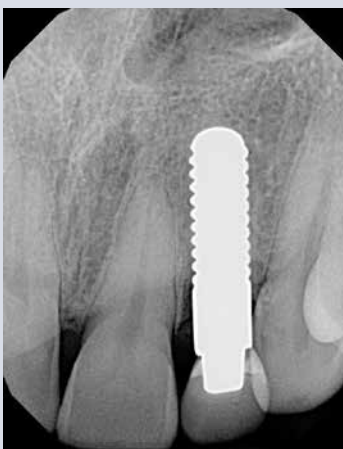

FIGURE 8—Post-operative radiograph.

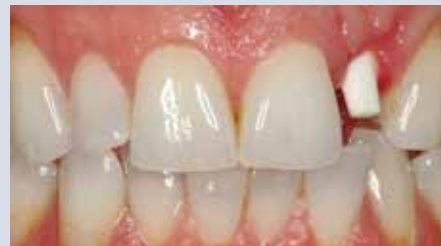

FIGURE 9—Healed implant three months post surgery.

used for seven days post operatively as well as Decadron 10mg with a three day tapering dosing regiment. One carpule of four percent articaine 1:200,000 epinephrine (Septocaine, Septodont Inc.) was used to anesthetize the operative area. A mini flap was raised sparing the papilla and the osteotomy was preformed utilizing very efficient ceramic drills at 300RPM, the slow drilling helps maintain the vitality of the bone. A closed mouth drilling technique was utilized to allow for ideal angulation (Fig. 4). A

CeraRoot 12 of 12 mm length (indicated for upper laterals) implant was selected for this case. The implant was placed (Fig. 5) at 30Ncm of initial stability with the buccal restorative margin placed where desired, about 0.5mm below the gingival margin (Figs. 6 & 8). Absorbable sutures (Coated Vicryl, Ethicon) were used to stabilize the flap and

an immediate provisional crown was fabricated out of a bisacryl (Luxatemp, DMG-America) and cemented with a small amount of provisional cement (CLING2, Clinician's Choice Dental Products, Inc.) (Fig. 7).

Prosthetic Treatment

After three months of healing the soft tissue healed and the implant integrated and was now ready for final restoration (Figs. 8-11). A digital scan utilizing iTero (Cadent, NJ) was taken and an E.max crown was lab

CASE 1

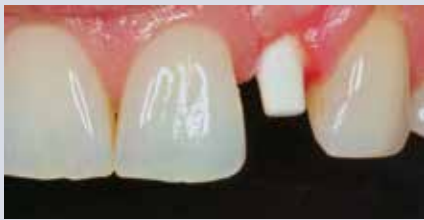

FIGURE 10—Healed site up close showing soft tissue overgrowth.

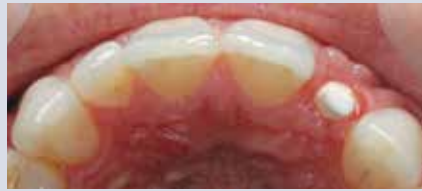

FIGURE 11—Healed site occlusal view. Soft tissue profile is ideal.

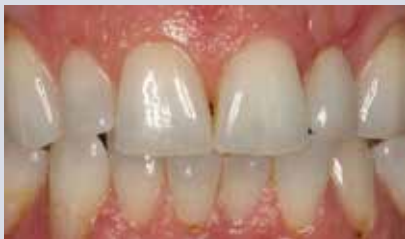

FIGURE 13—Day of cementation of final crown.

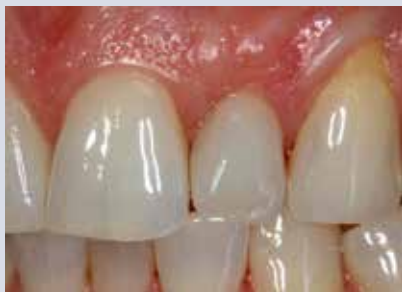

FIGURE 14—One-year in function.

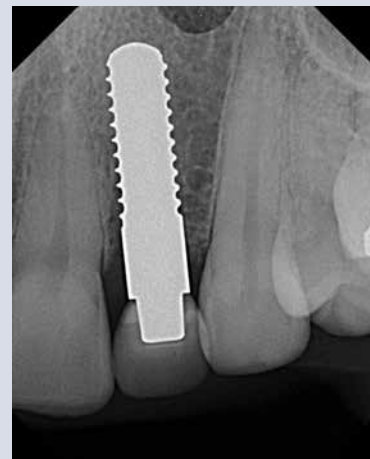

FIGURE 12—Three-month radiograph. Nearly no bone remodeling is seen.

fabricated. The crown was tried in and inserted with a composite resin cement (Maxcem Elite, Kerr Dental) (Fig. 13). Occlusion was adjusted as to avoid lateral contacts. Special attention was made to adjust the final occlusion of the crown slightly in infra-occlusion, avoiding lateral contacts and the anterior guidance. This is important to compensate the elasticity of the periodontium of the neighboring teeth, in contrast of the rigidity of the ceramic implant and crown. The final result, one year after function, shows healthy soft tissue without any signs of inflammation around the CeraRoot acid-etched surface (Fig. 14). Moreover, the periapical radiograph shows that bone is stable around the implant and there is no evidence of early bone remodeling.

CASE 2 PRESENTATION

Diagnosis

The patient, a 60-year-old female, non-smoker in good general health, presented with pain in a previously endodontically treated tooth #46. History revealed that

the tooth has been feeling tender for about two years ever since the endodontic treatment was completed. Radiographic and clinical exam revealed a fractured instrument in the mesial canal (Fig. 15) and a possible vertical root fracture. Class II stable occlusion was noted. Buccal recession was evident in both upper and lower teeth with thin scalloped tissues, otherwise healthy periodontal tissues.

Treatment Plan

Orthograde retreatment and retrograde endodontics were discussed as well as extraction and placement of an implant and implant-retained crown. However, due the possibility of a vertical fracture present, over all cost of treatment and deemed lower success rates it was decided that the implant would present the desired treatment. The possibility of the use of a zirconia one-piece dental implant (CeraRoot, Oral Iceberg) was discussed. The size of the CeraRoot implant presented an increased surface area for osseointegration especially

since we would be placing the implant immediately after extraction. The transgingival area of the CeraRoot implant would provide us with a built in emergence profile making the final restoration simple and functional with very little in terms of prosthetic complications.

Surgical Treatment

The patient was pre-medicated with an antibiotic (Amoxicillin 500mg), which was to be continued for seven days post operatively, as well as Decadron 10mg with a three day tapering dosing regiment. 1 carpule of four percent articaine 1:200,000 epinephrine (Septocaine, Septodont Inc.) was used to anesthetize the operative area. The tooth was sectioned and atraumatically removed and the sockets thoroughly curetted and irrigated with saline solution. The osteotomy was preformed with very efficient ceramic drills at 300RPM into the intraseptal bone extending 3mm beyond the apices of the tooth. A CeraRoot 16 of 10 mm length (indicated for molars) implant was selected for

CASE 2

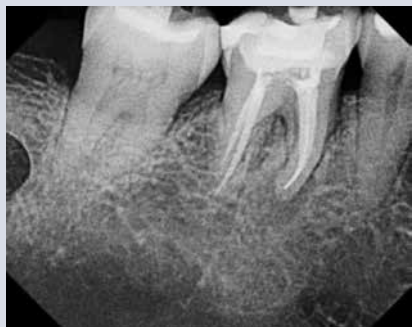

FIGURE 15—Pre-operative radiograph.

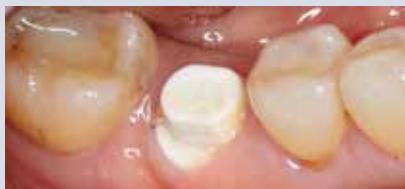

FIGURE 16—After four months of healing.

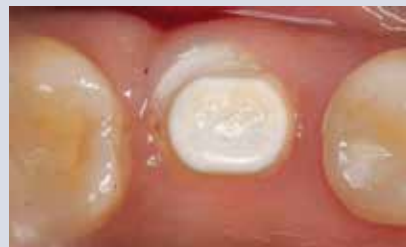

FIGURE 17—Occlusal view — note the soft tissue overgrowth.

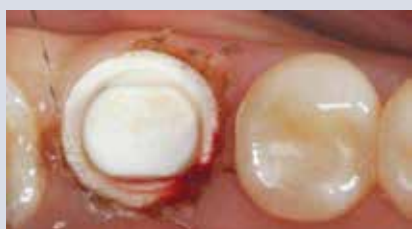

FIGURE 18—Margin exposed with soft tissue laser.

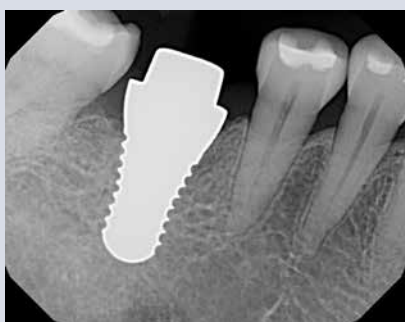


FIGURE 19—Radiograph showing bone volume after four-months of healing.

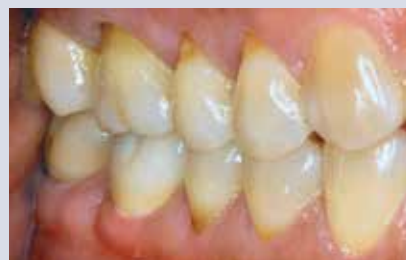

FIGURE 20—Final crown cemented, perfect prosthesis integration

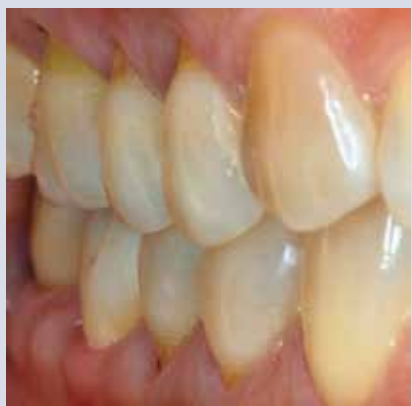

FIGURE 21—Beautiful soft tissue profile

this case. The implant was placed at $>35\text{Ncm}$ of initial stability with the buccal restorative margin placed where desired about 0.5mm below the desired gingival margin. The voids around the implant were all sealed by the large transgingival collar and thus, no graft or sutures were used. The tooth was not temporized due to the posterior location of the site and the patient was instructed to

eat in the contralateral part of the mouth for two months after healing. After four months of uneventful healing, the soft tissue matured and was ready for restoration (Figs. 16, 17). The soft tissue overgrew the restorative margin of the implant and as such a laser (Picasso, AMD Lasers) was used at 2.0W pulsed to expose the margins (Fig. 18) and a digital scan utilizing iTero (Cadent, NJ) was taken. A Prettau (Zirkonzahn, Gais) zirconia crown was made with zirconia in all functional areas and porcelain added on the

Prosthetic Treatment

After four months of uneventful healing, the soft tissue matured and was ready for restoration (Figs. 16, 17). The soft tissue overgrew the restorative margin of the implant and as such a laser (Picasso, AMD Lasers) was used at 2.0W pulsed to expose the margins (Fig. 18) and a digital scan utilizing iTero (Cadent, NJ) was taken. A Prettau (Zirkonzahn, Gais) zirconia crown was made with zirconia in all functional areas and porcelain added on the

buccal of the crown for aesthetics (Figs. 20, 21). The crown was tried in and inserted with a composite resin cement (Maxcem Elite, Kerr Dental). Occlusion was adjusted as to avoid lateral contacts.

Discussion

A high degree of clinical success can be achieved using a zirconium oxide dental implant.^{4,5,6,7,8} The great aesthetic potential, restorative simplicity and surface roughness make this system ideal for immediate tooth replacement. Periodontal health is amplified by the absence of a connection and microgap, and the affinity of the gingival complex to the zirconia oxide surface. Long-term success has been demonstrated in the literature. Case selection is crucial as ideal angulation is imperative.

The CeraRoot implant clearly demonstrates the capacity to in-

tegrate with bone, the strength needed to function in the oral environment and the prosthetic simplicity afforded by a one-piece design.

It is the author's opinion that this will soon become the implant of choice for tooth replacement. **OH**

Dr. Dan Hagi received his dental training at the University of Toronto and now maintains a multidisciplinary implant and rehabilitative practice in Thornhill, Ontario. He is an associate Fellow of the American Academy of Implant Dentistry(AAID), a Fellow of the International Congress of Oral Implantology(ICOI), a Fellow of the Academy of General Dentistry (AGD) and the Misch International Implant Institute. His private practice focuses on

metal free, minimally invasive rehabilitation and aesthetic smile design. He is a lecturer and mentor as well as a consultant on emerging metal-free materials and techniques.

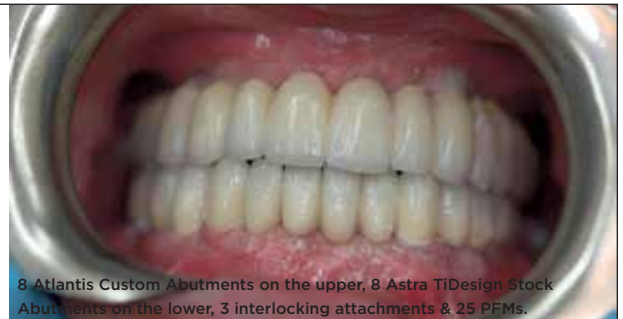Oral Health welcomes this original article.

REFERENCES

1. Akagawa Y, Ichikawa Y, Nikai H, Tsuru H. Interface histology of unloaded and early loaded partially stabilized zirconia endosseous implant in initial bone healing. *J Prosthet Dent.* 1993 Jun;69(6):599-604.
2. Akagawa Y, Hosokawa R, Sato Y, Kamayama K. Comparison between freestanding and tooth-connected partially stabilized zirconia implants after two years' function in monkeys: a clinical and histologic study. *J Prosthet Dent.* 1998 Nov;80(5):551-8.
3. Lekholm U, Gröndahl K, Jemt T. Outcome of oral implant treatment in partially edentulous jaws followed 20 years in clinical function. *Clin Implant Dent Relat Res.* 2006;8(4):178-86.
4. Oliva J, Oliva X, Oliva JD. Zirconia implants and all-ceramic restorations for the aesthetic replacement of two central incisors. *EJED* 2008;3(2):175-185.
5. Oliva J, Oliva X, Oliva JD. Ovoid Zirconia Implants: Anatomic Design for Premolar Replacement. *Int J Period Rest Dent* 2008; 28:609-615.
6. Oliva J, Oliva X, Oliva JD. Replacement of congenitally missing maxillary permanent canine with a

- zirconium oxide dental implant and crown. A case report from an ongoing clinical study. *Oral Surgery* 2008;1(2):140-144.
7. Oliva J, Oliva X, Oliva JD. Full mouth oral rehabilitation in a titanium allergy patient using zirconium oxide dental implants and zirconium oxide restorations A case report from an on-going clinical study. *EJED;* 2010 Summer; 5(2):190-203.
8. Oliva J, Oliva X, Oliva JD. Five year success rate of first consecutive 831 zirconia dental implants in humans. A comparison of three different rough surfaces. *JOMI* 2010 Mar-Apr;25(2):336-44
9. Mobilio N, Stefanoni F, Contiero P, Mollica F, Catapano S. Experimental and numeric stress analysis of titanium and zirconia one-piece dental implants. *Int J Oral Maxillofac Implants.* 2013 May-Jun;28(3):e135-42.
10. Andreiotelli M, Wenz HJ, Kohal RJ. Are ceramic implants a viable alternative to titanium implants? A systematic literature review. *Clin Oral Implants Res.* 2009 Sep;20 Suppl 4:32-47.
11. Saulacic N, Erdösi R, Bosshardt DD, Gruber R, Buser D. Acid and Alkaline Etching of Sandblasted Zirconia Implants: A Histomorphometric Study in Miniature Pigs. *Clin Implant Dent Relat Res.* 2013 Apr 9.
12. Delgado-Ruiz RA, Calvo-Guirado JL, Abboud M, Ramirez-Fernandez MP, Mate-Sanchez JE, Negri B, Rothamel D. Histologic and Histomorphometric Behavior of Microgrooved Zirconia Dental Implants with Immediate Loading. *Clin Implant Dent Relat Res.* 2013 Apr 5.
13. Oliva X, Oliva J, Oliva JD, Prasad HS, Rohrer MD. Osseointegration of Zirconia (Y-TZP) Dental Implants: A Histologic, Histomorphometric and Removal Torque Study in the Hip of Sheep. *Int J Oral Implantol Clin Res* 2013;4(2):00-00.

Real cases. Real pictures.
A lab for all your real needs.



8 Atlantis Custom Abutments on the upper, 8 Astra TIDesign Stock Abutments on the lower, 3 interlocking attachments & 25 PFMs.

We don't need stock photography, we use real pictures of our cases to showcase our work. Our technicians are specially trained both internally and externally around the world with the best, helping them take implant and cosmetic dentistry to the next level. But, while cosmetic dentistry can improve a patient's look, we first focus on improving the strength, function and longevity of their smile.

With a top of the line CAD/CAM arsenal, in-lab milling machine and quality technicians, our lab has earned a reputation for advanced implant experience, high-end aesthetics and quality results.

Specialists in:

Treatment Planning, Cosmetic Dentistry, Custom Shading, Implantology, Crown & Bridge, Removable Prosthetics and CAD/CAM



THE SCIENCE TO MAKE IT RIGHT.
 THE TALENT TO MAKE IT BEAUTIFUL.™

GORDANADENTALARTS.COM
 416.785.6690 1.800.460.0211